
Evaluation of White Spot Lesions on Teeth with Orthodontic Brackets

Philip Benson

Accurate evaluation of demineralized white spot lesions during orthodontic treatment is important to both clinicians, so they might implement early prevention and/or treatment, and researchers who wish to study the effectiveness of those methods. Assessment will depend on accurate detection and measurement of a lesion, using procedures that demonstrate good validity and reproducibility. A range of evaluative techniques are outlined and the advantages and disadvantages of each are discussed. Some methods can be applied by the busy clinician, whereas others are more suitable for the researcher undertaking a clinical trial. Regardless of who is using the technique, it should be relatively straightforward to apply in the clinical situation, and whatever technique is undertaken, researchers and clinicians must appreciate the need for proper research designs to produce reliable information regarding the effectiveness of any intervention. (Semin Orthod 2008;14:200-208.) © 2008 Elsevier Inc. All rights reserved.

The evaluation of demineralized white spot lesions during orthodontic treatment is important for both clinicians and researchers. Clinicians must discover enamel lesions early so that they can advise their patients regarding changes in oral hygiene and diet, as well as implement suitable preventive measures. Accurate evaluation of demineralization is essential for research workers to assess new products or interventions, which might help prevent the appearance of demineralized lesions during orthodontic treatment. Evaluation will depend on accurate detection and measurement of a lesion.

If a form of assessment is to be relied on to produce accurate detection and measurement then it must fulfill several criteria.

Validity

The method of assessment should determine that the white spot is caused by mineral loss from enamel by acid demineralization during orthodontic treatment, rather than an opacity that may have been present before the appliance was placed, the causes of which are numerous.¹ A trained and experienced observer will usually be able to distinguish between the two (Fig 1).

Reproducibility

Any form of assessment needs to be reproducible so that a reading taken by a single assessor on one occasion is very similar to a reading taken by the same assessor on an unchanged lesion at another time. Also there should be very little difference between readings of an identical lesion performed by different assessors. Both clinicians and researchers need to distinguish between those lesions that were present before the appliance was placed and those developing during treatment. To ensure this the assessments need to be reproducible over a long period of time, as they should be performed at the start and at the end of treatment, which might be several years later, especially if improvement

Senior Lecture/Honorary Consultant in Orthodontics, Department of Oral Health and Development, School of Clinical Dentistry, University of Sheffield, Sheffield, UK.

Address correspondence to Philip Benson, PhD, FDS (Orth), University of Sheffield, School of Clinical Dentistry, Department of Oral Health and Development, University of Sheffield, Sheffield, UK S10 2TA. Phone: 44 114 2717885; Fax: 44 114 2717843; E-mail: p.benson@sheffield.ac.uk

© 2008 Elsevier Inc. All rights reserved.

1073-8746/08/1403-0\$30.00/0

doi:10.1053/j.sodo.2008.03.005

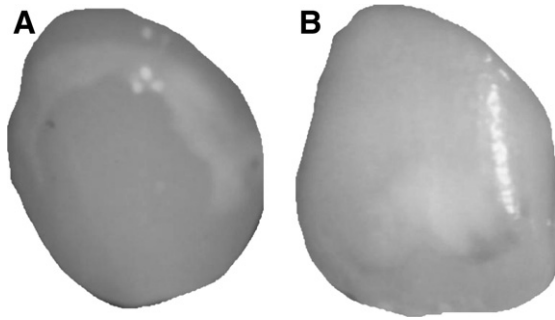


Figure 1. Examples of postorthodontic white spot demineralization (A) and a developmental opacity (B).

in the lesion over time after removal of the appliance is to be followed up.

Ease of Use

Clinicians require a technique that can be easily applied to their clinical practice and is relatively inexpensive. An instrument that produces an accurate reading of demineralization, but requires half an hour to set up, will not be used. Research workers might allow more time and use more sophisticated instruments to obtain precise assessments; however, they are still restrained by issues of practicality and flexibility if they are going to assess outcomes in a sufficient number of patients and a wide range of settings to get meaningful results.

Any evaluation requires two outcomes to be assessed. The first outcome is to decide if demineralization is present or not. The second outcome is to measure the severity of the lesion. Severity might be expressed macroscopically in terms of the area and the relative difference in the whiteness of the lesion compared with the surrounding sound enamel or microscopically by the amount of mineral loss or lesion depth. It is essential to assess both outcomes if a realistic assessment of an intervention is to be obtained because a product may not completely prevent demineralization but may reduce the area of the tooth surface affected or the amount of mineral loss and lesion depth.

There are macroscopic and microscopic methods used in the detection and measurement of demineralized white lesions.

Macroscopic Methods

Macroscopic methods rely mainly on the change in optical properties of enamel with demineralization. A demineralized lesion in enamel is white is due to an increase in the backscatter of light. Sound enamel is a low light scattering material. When a light photon enters sound enamel, it travels an average distance of 0.1 mm before being scattered.² A large portion of light penetrates the enamel, which is about 1 mm thick and is backscattered by dentine, which is why the color of dentine is often more clinically apparent than the color of enamel. When mineral is lost from enamel it becomes more porous. The mineral is partly replaced by water, leading to an increased difference in refractive index between sound and demineralized enamel. A light photon travels a much shorter distance in carious enamel before being backscattered. Most photons are scattered within the lesion, rather than penetrating to dentine, and the backscatter is greater, resulting in the clinical appearance of a white spot. When the lesion is dried, the water is replaced by air and the average refractive index declines even more, leading to an even whiter lesion.

There are various macroscopic techniques for assessing enamel demineralization.

Clinical Examination

Clinicians are trained to use a clinical examination to assess the presence of demineralization. Several clinical orthodontic studies have employed a visual examination to assess demineralization before, during, or after orthodontic treatment.³⁻¹² There are advantages and disadvantages to relying on this method.

Advantages

- Simple and inexpensive—no expensive or complex equipment is required.
- Clinically valid—what the examiner sees and measures is likely to be the patient's perceived problem.

Disadvantages

- Validity—it is often difficult clinically to distinguish white spots caused by demineralization

and those that are due to other causes, such as developmental hypoplasia or fluorosis.

In a clinical trial, using adequate methods to reduce the risk of bias, such as masking of examiners, can be more demanding. In addition, reducing inter-examiner error by adequate calibration before and during a trial may be time consuming and inaccurate. Assessment of intra-examiner error involves recalling individuals for remeasuring that may be inconvenient to the patient and may lead to the establishment of a convenience sample for error assessment.

Clinical studies have used many different indices to assess demineralization. Some of the studies have been less than rigorous when describing aspects of the investigation such as calibration and blinding of examiners, as well as methods of error assessment including both systematic and random error.

Photographic Examination

Photographic techniques have been used extensively to study the prevalence of enamel opacities¹³⁻²³ and early investigations into the mechanisms of enamel demineralization.^{24,25} Several clinical orthodontic studies have also used photographs as a means of assessing demineralization before, during, or after orthodontic treatment.²⁶⁻³⁴

Advantages

- Many orthodontists now routinely take photographs as part of a patients' clinical record. Clinicians are therefore familiar with the technique and can carry it out quickly and efficiently in most settings. The method used can be standardized so that clinical variability of diagnostic conditions may be minimized.
- Photographs provide a permanent record and can therefore be examined during one assessment session and re-examined at a different time to determine reproducibility.
- It is easy to mask the patient details so they can be examined in a random order to reduce the potential for bias.
- Photographs taken by several examiners may be scored by one independent expert to remove the effects of intra-examiner variability.
- Photographs are more versatile than a visual examination. They might be used to assess the presence or absence of demineralization by

several trained judges to obtain a consensus. They can also be digitized and a computer used to measure the severity of the lesion in terms of area or change in whiteness or gray levels.^{35,36}

Disadvantages

- The camera might record details differently than the naked eye. Photographs tend to overestimate the incidence of opacities, partly due to the reflection of the flash from the tooth surface (Fig 2). The problems of extraneous light can be reduced by slanting the camera slightly³⁷ or by filtering out the flash using cross-polarizing filters³⁸ (Fig 3).
- Standardization of the procedures may be difficult, particularly with respect to the wetness of the tooth, but also lighting conditions might differ. Film types and processing methods will vary for conventional photography, although the quality of digital photography and the cost of equipment are now at a level to use routinely in the clinic and for research.³⁹

Optical Nonfluorescent Methods

Light Scattering

As explained earlier, demineralization leads to more scattering of the light entering enamel. The scattering results in a sideward displacement of the light, which can be measured using the Optical Caries Monitor (OCM) first described by Ten Bosch and coworkers.^{40,41} They used a 100-W white light as a light source and measured backscatter with a densitometer. They showed a good correlation between the OCM readings and other more direct, but destructive methods of measuring mineral loss.⁴² This method has been used in one clinical study.⁴³



Figure 2. An apparent white lesion caused by reflection from the camera flash.

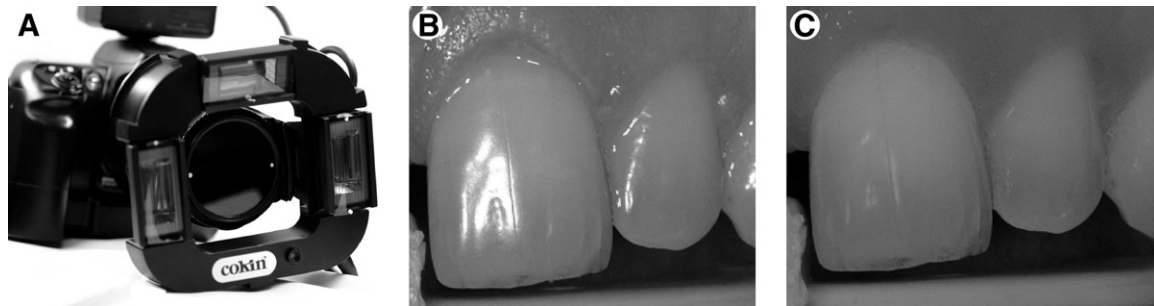


Figure 3. A digital camera with cross-polarizing filters placed to reduce reflection from the flash. The white marks show the direction in which the filter polarizes the light. Note that those placed on the lens and those placed on the images of the incisors taken without (B) and with (C) cross-polarizing filters (courtesy of Professor D.R. Willmot).

The advantage of the OCM is that it enables a convenient and nondestructive quantification of enamel demineralization. It can be applied in the clinical environment and has been correlated with established methods of studying mineral loss. The disadvantage is that it is particularly technique sensitive and results can vary with the degree of wetness or drying of the tooth.

Optical Fluorescent Methods

The property of fluorescence is a function of light absorption.² A material that absorbs light will be more fluorescent than a material that reflects light. As previously explained, demineralization leads to more backscatter of light, hence less absorption and a lower intensity of fluorescence. Carious enamel will therefore show up as a dark area with fluorescent techniques.

There are a number of different techniques for producing fluorescence in enamel.

Fluorescent Dye Uptake

Various fluorescent and nonfluorescent dyes have been used to highlight carious enamel.⁴⁴ Once the fluorescent dye has been applied, the specimen is examined under a suitable light source. The disadvantage of these dyes is that slight procedural variations can result in widely different degrees of dye uptake. They are mainly used for the detection and removal of carious dentine.⁴⁵

Ultraviolet

Early studies⁴⁶ used an ultraviolet (UV) light for the early detection of carious lesions on the smooth surfaces. Special precautions are required to protect the patient and operator because UV radiation, which has a wavelength shorter than visible light (<400 nm), is harmful to the eyes and skin. Safer methods using light sources with a longer wavelength have been developed.

Laser

Bjerkhagen and coworkers⁴⁷ used an argon laser to show differences in luminescence from intact and carious enamel in the laboratory. De Josselin de Jong and coworkers⁴⁸ developed the technique of quantitative laser fluorescence for use in the mouth. They used an argon-ion laser producing light in the blue-green range of the electromagnetic spectrum (440-570 nm). A yellow high-pass filter was used on the detection equipment to cut off light with a wavelength of less than 520 nm (the blue and lower green range). This ensured that tooth scattered blue laser light did not reach the detection apparatus, but allowed fluorescence in the yellow region (wavelength 565-590 nm) to be measured. As with all fluorescence techniques, the demineralized lesions appear as dark areas (decreased fluorescence or absorption). The equipment was calibrated to calculate the difference in fluorescence between the demineralized area and the surrounding sound enamel and thereby quantify mineral loss and lesion size.

Quantitative laser fluorescence was used to study the change in fluorescence with time of teeth exhibiting white spot lesions following orthodontic treatment.⁴⁹ The results showed that radiance levels increased and the area of almost all white spot lesions decreased over time suggesting mineral gain. Remineralization of the lesions showed an exponential pattern with most mineral gain occurring early, then the rate slowing down.

Another method using laser fluorescence is an instrument called DIAGNODent (KaVo, Germany). It is a portable system, which emits light of wavelength 655 nm or the red end of the electromagnetic spectrum. DIAGNODent does not produce a picture of the tooth, but produces a reading, which is thought to be an indication of bacterial activity, rather than mineral loss. It was shown to produce reproducible readings in 13 orthodontic patients who had recently been debonded.⁵⁰ It has also been used to evaluate two ways of managing individuals with demineralized white spots following orthodontic treatment.⁵¹ Twelve individuals were randomly allocated to two groups and followed up every 3

months for 1 year. The control group received oral hygiene instruction and the experimental group received oral hygiene instruction and professional tooth cleaning. They found that the mean DIAGNODent readings were lower at 12 months than at debond suggesting that the lesions improved, but that there was no difference between the two groups.

Light (Quantitative Light-Induced Fluorescence or QLF)

A major problem with the laser system was the size of the light source equipment, which limited the practical use of this technique. A smaller portable system for intraoral use has been developed with a new light source and filter system⁵² (Fig 4). This is the basis of the most promising fluorescent method of measuring demineralization in use today. It employs an arc lamp with a liquid light guide. The light is passed through a blue filter in front of the lamp, with a peak intensity of 370 nm. The yellow high pass filter (<540 nm) is maintained in front of the detecting camera to

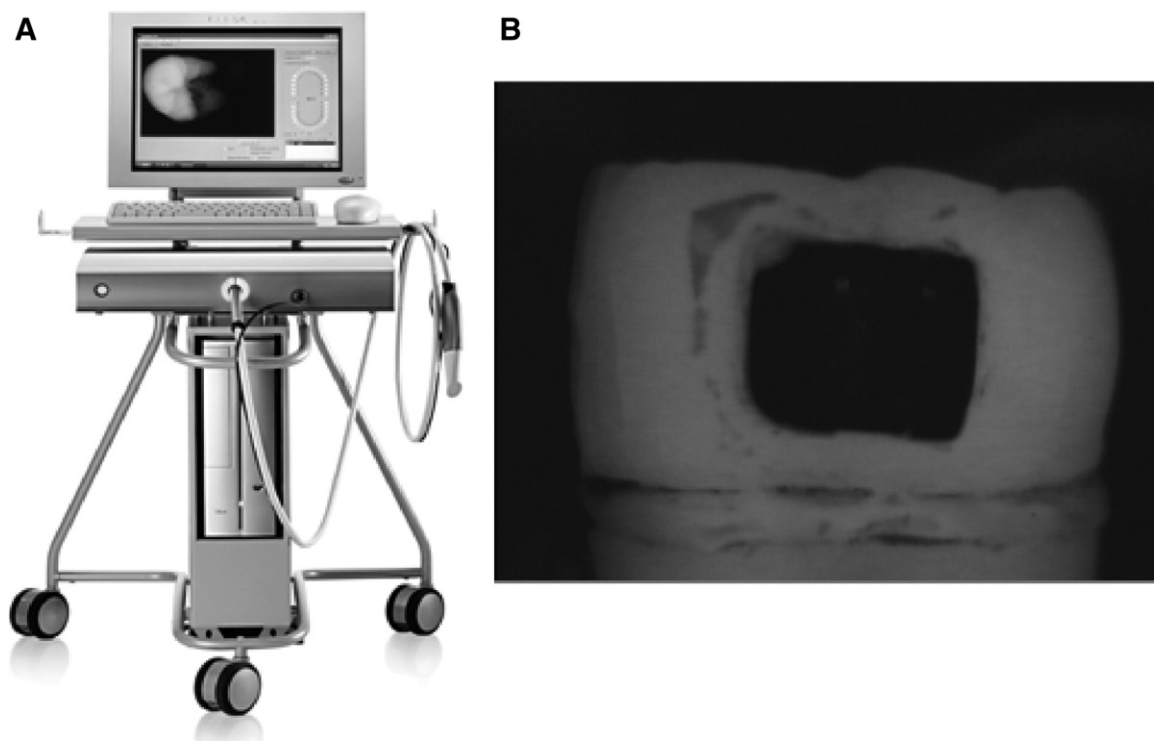


Figure 4. Quantitative light-induced fluorescence light source and capture equipment (A) and image (B) of an extracted tooth showing areas of reduced absorption, such as the bracket and artificially demineralized area as dark (reproduced with permission by Inspektor Research Systems BV, Amsterdam, The Netherlands).

exclude scattered blue light and the combination is optimized so there are no reflections. The images are stored, processed, and analyzed with custom software. The software is even designed to ensure that reproducible images of the tooth are taken over a period of time.

QLF has been shown in the laboratory to be a useful technique that may be applied to orthodontic patients.^{35,36,53,54} It has recently been used in 55 subjects to evaluate the change in the fluorescence of 406 surfaces with demineralized lesions following orthodontic treatment.⁵⁵ The majority of lesions (61%) did not change during the 6-month observation period after removal of the fixed appliances. Approximately one third (29%) of the lesions improved, but a significant minority (10%) actually got worse, and it was noted that these were mainly early lesions.

The potential of QLF has yet to be fully exploited. It is an exciting technique that not only enables early detection of demineralized lesions, but also detects changes in the mineral loss and size over time. It will undoubtedly prove useful to both clinicians and research workers in the future.

Microscopic Methods

Caries Models

For many years cariologists have used models to study both demineralization and remineralization in the mouth. Orthodontic caries models have usually involved placing a band⁵⁶⁻⁶¹ or a bracket⁶² on a tooth that is destined for extraction. Following a period in the mouth, the tooth is extracted. It is then examined using one of the destructive methods of measuring mineral loss and lesion depth such as microhardness testing, polarized light microscopy, or microradiography. These techniques have been used in a number of interventional clinical trials.⁶³⁻⁷⁰

These in vivo banding techniques allow direct measurement of mineral loss or lesion depth in enamel, but have a number of disadvantages.⁷¹ These include the lack of availability of teeth and only patients requiring extractions can participate. There is less control over lesion reproducibility and restrictions regarding lesion location. The patient cannot commence their orthodontic treatment until the tooth is extracted. Consequently, the length of the experiment is limited; otherwise the patient's treatment will be unduly prolonged.

The experiment is confined to the initial stages of treatment, usually the first month, whereas orthodontics can take up to 2 years. This technique is therefore unable to monitor changes in the enamel throughout the duration of the treatment. There may also be a longer time for treatment effects. The advantages of the technique include the fact that the teeth are in their most natural state with original surface pellicle and under natural occlusion, position, and function.

The In Situ Caries Model

A more sophisticated technique for investigating the processes of demineralization and remineralization is called the in situ caries model. This involves using a section of enamel, rather than a whole tooth. The enamel is placed in a removable appliance worn by a volunteer, bonded to the tooth of a volunteer, or placed in a specially designed holder attached to the orthodontic archwire⁷² (Fig 5). After a suitable intervention or time period, the specimen is removed and examined. This technique has a number of advantages over the extracted tooth model⁷³:

- The model reproduces the natural caries process without causing irreversible damage to the volunteer.
- specimen of the same tooth may be kept as a control, allowing a more accurate determination of the changes that occur.
- It is possible to induce an artificial subsurface lesion in the specimen, so that remineraliza-

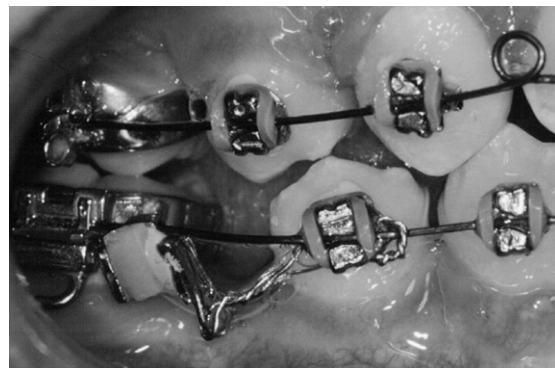

Figure 5. In situ enamel sample in a custom-made holder placed on the archwire mesial to the lower molar band (from Doherty and coworkers. Fluoride-releasing elastomeric ligatures assessed with the in situ caries model. *Eur J Orthod* 2002;24:371-378, reproduced by permission Oxford University Press).

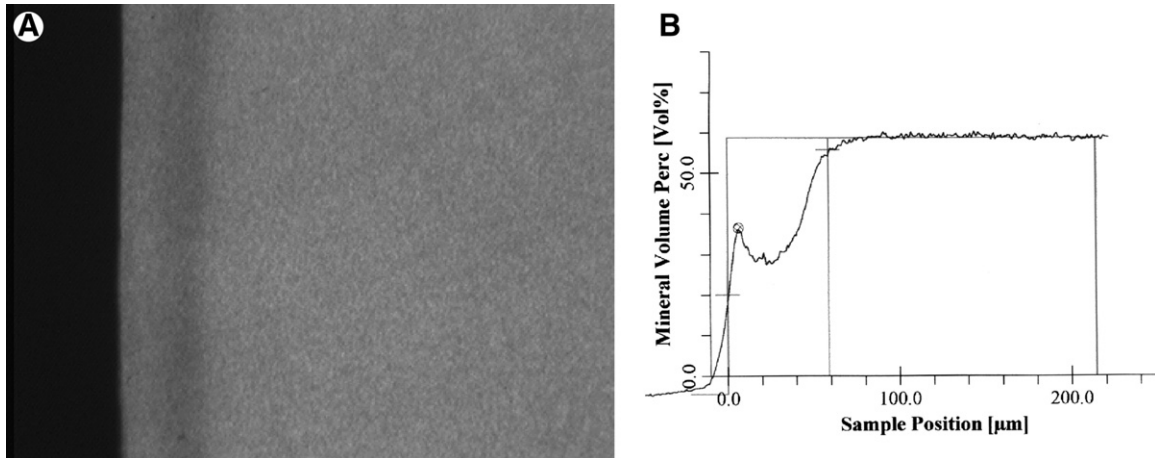


Figure 6. Microradiograph of enamel used as an in situ sample showing a subsurface lesion (A) and computerized analysis of the lesion with calculation of mineral loss and lesion depth (B).

tion as well as further demineralization can be studied.

- The enamel specimen may be examined using well-tested methods of measuring mineral loss and lesion depth, such as microradiography (Fig 6).
- The model allows more flexibility of the experimental design, such as crossover studies.
- It will not affect the orthodontic treatment.
- It can be used throughout a course of orthodontic treatment.

The main disadvantage of the in situ model is that it is very time consuming, particularly in laboratory and analysis time. Therefore, the number of subjects in these trials is limited to between 5 and 40. This raises the question of whether such a small number is representative of the population.

The in situ model has been used in one longitudinal, prospective, randomized, crossover clinical trial examining the benefit of fluoride-releasing elastomeric ligatures⁷⁴ in 14 individuals with fixed orthodontic appliances. No difference was found in the mineral loss and lesion depth between the three enamel specimens that had been present in the mouth with the fluoridated elastomeric ligatures, the nonfluoridated ligatures, and the control.

Research Methods

Finally, as a researcher in the field, my main purpose in establishing accurate methods of

evaluation is to develop the means by which potential preventive agents can be assessed. It is essential that investigators use properly controlled trials to reduce bias from selection, allocation, and assessment. In particular, clinical studies should be prospective, with clear inclusion and exclusion criteria, random allocation to treatment and control groups, masking of outcome assessment, and withdrawals and drop-outs accounted for. The reporting and statistical methods should be sound, including a sample size calculation to ensure the study has sufficient numbers of participants to find a clinical difference if one exists and the use of appropriate statistical tests that take into account that teeth within individuals are not independent of each other.

References

1. Murray JJ, Shaw L: Classification and prevalence of enamel opacities in the human deciduous and permanent dentitions. *Arch Oral Biol* 24:7-13, 1979
2. Angmar-Mansson B, ten Bosch JJ: Optical methods for the detection and quantification of caries. *Adv Dent Res* 1:14-20, 1987
3. Gillgrass TJ, Benington PC, Millett DT, Newell J, et al: Modified composite or conventional glass ionomer for band cementation? A comparative clinical trial. *Am J Orthod Dentofacial Orthop* 120:49-53, 2001
4. Ogaard B, Larsson E, Henriksson T, et al: Effects of combined application of antimicrobial and fluoride varnishes in orthodontic patients. *Am J Orthod Dentofacial Orthop* 120:28-35, 2001
5. Alexander SA, Ripa LW: Effects of self-applied topical fluoride preparations in orthodontic patients. *Angle Orthod* 70:424-430, 2000

6. Banks PA, Chadwick SM, Asher-McDade C, et al: Fluoride-releasing elastomers—a prospective controlled clinical trial. *Eur J Orthod* 22:401-407, 2000
7. Gaworski M, Weinstein M, Borislow AJ, et al: Decalcification and bond failure: a comparison of a glass ionomer and a composite resin bonding system in vivo. *Am J Orthod Dentofacial Orthop* 116:518-521, 1999
8. Banks PA, Burn A, O'Brien K: A clinical evaluation of the effectiveness of including fluoride into an orthodontic bonding adhesive. *Eur J Orthod* 19:391-395, 1997
9. Boyd RL: Long-term evaluation of a SnF₂ gel for control of gingivitis and decalcification in adolescent orthodontic patients. *Int Dent J* 44:119-130, 1994
10. Boyd RL: Comparison of three self-applied topical fluoride preparations for control of decalcification. *Angle Orthod* 63:25-30, 1993
11. Geiger AM, Gorelick L, Gwinnett AJ, et al: Reducing white spot lesions in orthodontic populations with fluoride rinsing. *Am J Orthod Dentofacial Orthop* 101:403-407, 1992
12. Geiger AM, Gorelick L, Gwinnett AJ, et al: The effect of a fluoride program on white spot formation during orthodontic treatment. *Am J Orthod Dentofacial Orthop* 93:29-37, 1988
13. Cochran JA, Ketley CE, Arnadottir IB, et al: A comparison of the prevalence of fluorosis in 8-year-old children from seven European study sites using a standardized methodology. *Community Dent Oral Epidemiol* 32(Suppl 1):28-33, 2004
14. Sabieha AM, Rock WP: A comparison of clinical and photographic scoring using the TF and modified DDE indices. *Community Dent Health* 15:82-87, 1998
15. Ellwood RP, Cortea DF, O'Mullane DM: A photographic study of developmental defects of enamel in Brazilian school children. *Int Dent J* 46:69-75, 1996
16. Ellwood RP, Hawew RM, Worthington HV, et al: Developmental enamel defects and extrinsic tooth stain in Libyan schoolchildren. *Community Dent Oral Epidemiol* 24:419-420, 1996
17. Ellwood RP, O'Mullane DM: Dental enamel opacities in three groups with varying levels of fluoride in their drinking water. *Caries Res* 29:37-142, 1995
18. Nunn JH, Ekanayake L, Rugg-Gunn AJ, et al: Assessment of enamel opacities in children in Sri Lanka and England using a photographic method. *Community Dent Health* 10:175-188, 1993
19. Nunn JH, Murray JJ, Reynolds P, et al: The prevalence of developmental defects of enamel in 15-16-year-old children residing in three districts (natural fluoride, adjusted fluoride, low fluoride) in the north east of England. *Community Dent Health* 9:235-247, 1992
20. Ishii T, Suckling G: The severity of dental fluorosis in children exposed to water with a high fluoride content for various periods of time. *J Dent Res* 70:952-956, 1991
21. Dooland MB, Wylie A: A photographic study of enamel defects among South Australian school children. *Aust Dent J* 34:470-473, 1989
22. Levine RS, Beal JF, Fleming CM: A photographically recorded assessment of enamel hypoplasia in fluoridated and non-fluoridated areas in England. *Br Dent J* 166:249-252, 1989
23. Houwink B, Wagg BJ: Effect of fluoride dentifrice usage during infancy upon enamel mottling of the permanent teeth. *Caries Res* 13:231-237, 1979
24. Hollender L, Koch G: Effect of local application of fluoride on initial demineralization of buccal surface of maxillary incisors. Clinical assessment from colour slides. *Sven Tandlak Tidsskr* 69:1-5, 1976
25. Edgar WM, Rugg-Gunn AJ, Jenkins GN, et al: Photographic and direct visual recording of experimental caries-like changes in human dental enamel. *Arch Oral Biol* 23:667-673, 1978
26. Mattick CR, Mitchell L, Chadwick SM, et al: Fluoride-releasing elastomeric modules reduce decalcification: a randomized controlled trial. *J Orthod* 28:217-219, 2001
27. Wenderoth CJ, Weinstein M, Borislow AJ: Effectiveness of a fluoride-releasing sealant in reducing decalcification during orthodontic treatment. *Am J Orthod Dentofacial Orthop* 116:629-634, 1999
28. Millett DT, Nunn JH, Welbury RR, Gordon PH: Decalcification in relation to brackets bonded with glass ionomer cement or a resin adhesive. *Angle Orthod* 69:65-70, 1999
29. Marcusson A, Norevall LI, Persson M: White spot reduction when using glass ionomer cement for bonding in orthodontics: a longitudinal and comparative study. *Eur J Orthod* 19:233-242, 1997
30. Trimpeneers LM, Dermaut LR: A clinical evaluation of the effectiveness of a fluoride-releasing visible light-activated bonding system to reduce demineralization around orthodontic brackets. *Am J Orthod Dentofacial Orthop* 110:218-222, 1996
31. Turner PJ: The clinical evaluation of a fluoride-containing orthodontic bonding material. *Br J Orthod* 20:307-313, 1993
32. Mitchell L: An investigation into the effect of a fluoride releasing adhesive on the prevalence of enamel surface changes associated with directly bonded orthodontic attachments. *Br J Orthod* 19:207-214, 1992
33. Adriaens ML, Dermaut LR, Verbeeck RM: The use of 'Fluor Protector', a fluoride varnish, as a caries prevention method under orthodontic molar bands. *Eur J Orthod* 12:316-319, 1990
34. Sonis AL, Snell W: An evaluation of a fluoride-releasing, visible light-activated bonding system for orthodontic bracket placement. *Am J Orthod Dentofacial Orthop* 95:306-311, 1989
35. Benson PE, Pender N, Higham SM: Quantifying enamel demineralization from teeth with orthodontic brackets—a comparison of two methods. Part 1: repeatability and agreement. *Eur J Orthod* 25:149-158, 2003
36. Benson PE, Pender N, Higham SM: Quantifying enamel demineralization from teeth with orthodontic brackets—a comparison of two methods. Part 2: validity. *Eur J Orthod* 25:159-165, 2003
37. Cochran JA, Ketley CE, Sanches L, et al: A standardized photographic method for evaluating enamel opacities including fluorosis. *Community Dent Oral Epidemiol* 32(Suppl 1):19-27, 2004
38. Robertson AJ, Toumba KJ: Cross-polarized photography in the study of enamel defects in dental paediatrics. *J Audio Media Med* 22:63-70, 1999
39. Benson PE, Shah AA, Willmot DR: Measurement of white lesions surrounding orthodontic brackets—captured slides v digital camera images. *Angle Orthod* 72:222-226, 2005

40. Ten Bosch JJ, Borsboom PC, ten Cate JM: A nondestructive method for monitoring de- and remineralization of enamel. *Caries Res* 14:90-95, 1980
41. Borsboom PCF, Ten Bosch JJ: Fiber-optic scattering monitor for use with bulk opaque material. *Applied Optics* 21:3531-3535, 1982
42. ten Bosch JJ, van der Mei HC, Borsboom PC: Optical monitor of in vitro caries. A comparison with chemical and microradiographic determination of mineral loss in early lesions. *Caries Res* 18:540-547, 1984
43. Ogaard B, Ten Bosch JJ: Regression of white spot enamel lesions. A new optical method for quantitative longitudinal evaluation in vivo. *Am J Orthod Dentofacial Orthop* 106:238-242, 1994
44. Rawls HR, Owen WD: Demonstration of dye-uptake as a potential aid in early diagnosis of incipient caries. *Caries Res* 12:69-75, 1978
45. Hosoya Y, Taguchi T, Tay FR: Evaluation of a new caries detecting dye for primary and permanent carious dentin. *J Dent* 35:137-143, 2007
46. Shrestha BM: Use of ultraviolet light in early detection of smooth surface carious lesions in rats. *Caries Res* 14:448-451, 1980
47. Bjelkhagen H, Sundstrom F, Angmar-Mansson B, et al: Early detection of enamel caries by the luminescence excited by visible laser light. *Swed Dent J* 6:1-7, 1982
48. De Josselin de Jong E, Sundstrom F, Westerling H, Tranaeus S, ten Bosch JJ, Angmar-Mansson B: A new method for in vivo quantification of changes in initial enamel caries with laser fluorescence. *Caries Res* 29:2-7, 1995
49. Al-Khateeb S, Forsberg CM, de Josselin de Jong E, et al: A longitudinal laser fluorescence study of white spot lesions in orthodontic patients. *Am J Orthod Dentofacial Orthop* 113:595-602, 1998
50. Aljehani A, Bamzahim M, Yousif MA, et al: In vivo reliability of an infrared fluorescence method for quantification of carious lesions in orthodontic patients. *Oral Health Prev Dent* 4:145-150, 2006
51. Aljehani A, Yousif MA, Angmar-Mansson B, et al: Longitudinal quantification of incipient carious lesions in postorthodontic patients using a fluorescence method. *Eur J Oral Sci* 114:430-434, 2006
52. al-Khateeb S, ten Cate JM, Angmar-Mansson B, et al: Quantification of formation and remineralization of artificial enamel lesions with a new portable fluorescence device. *Adv Dent Res* 11:502-506, 1997
53. Aljehani A, Tranaeus S, Forsberg CM, et al: In vitro quantification of white spot enamel lesions adjacent to fixed orthodontic appliances using quantitative light-induced fluorescence and DIAGNOdent. *Acta Odontol Scand* 62:313-318, 2004
54. Pretty IA, Pender N, Edgar WM, et al: The in vitro detection of early enamel de- and re-mineralization adjacent to bonded orthodontic cleats using quantitative light-induced fluorescence. *Eur J Orthod* 25:217-223, 2003
55. van der Veen MH, Mattousch T, Boersma JG: Longitudinal development of caries lesions after orthodontic treatment evaluated by quantitative light-induced fluorescence. *Am J Orthod Dentofac Orthop* 131:223-228, 2007
56. Hals E, Simonsen LT: Histopathology of experimental in vivo caries around silver amalgam fillings. *Caries Res* 6:16-33, 1972
57. Holmen L, Thylstrup A, Ogaard B, et al: A scanning electron microscopic study of progressive stages of enamel caries in vivo. *Caries Res* 19:355-367, 1985
58. Holmen L, Thylstrup A, Ogaard B, et al: A polarized light microscopic study of progressive stages of enamel caries in vivo. *Caries Res* 19:348-354, 1985
59. Ogaard B, Rolla G, Arends J: Orthodontic appliances and enamel demineralization. Part 1. Lesion development. *Am J Orthod Dentofacial Orthop* 94:68-73, 1988
60. Ogaard B, Rolla G, Arends J, et al: Orthodontic appliances and enamel demineralization. Part 2. Prevention and treatment of lesions. *Am J Orthod Dentofacial Orthop* 94:123-128, 1988
61. Melrose CA, Appleton J, Lovius BB: A scanning electron microscopic study of early enamel caries formed in vivo beneath orthodontic bands. *Br J Orthod* 23:43-47, 1996
62. O'Reilly MM, Featherstone JDB: Demineralization and remineralization around orthodontic appliances: an in vivo study. *Am J Orthod Dentofacial Orthop* 92:33-40, 1987
63. Ogaard B, Arends J, Schuthof J, et al: Action of fluoride on initiation of early enamel caries in vivo. A microradiographical investigation. *Caries Res* 20:270-277, 1986
64. Rezk-Lega F, Ogaard B, Arends J: An in vivo study on the merits of two glass ionomers for the cementation of orthodontic bands. *Am J Orthod Dentofacial Orthop* 99:162-167, 1991
65. Ogaard B, Rezk-Lega F, Ruben J, et al: Cariostatic effect and fluoride release from a visible light-curing adhesive for bonding of orthodontic brackets. *Am J Orthod Dentofacial Orthop* 101:303-307, 1992
66. Buyukyilmaz T, Tangugsorn V, Ogaard B, et al: The effect of titanium tetrafluoride (TiF₄) application around orthodontic brackets. *Am J Orthod Dentofacial Orthop* 105:293-296, 1994
67. Ullsfooss BN, Ogaard B, Arends J, et al: Effect of a combined chlorhexidine and NaF mouthrinse: an in vivo human caries model study. *Scand J Dent Res* 102:109-112, 1994
68. Czochrowska E, Ogaard B, Duschner H, et al: Cariostatic effect of a light-cured, resin-reinforced glass-ionomer for bonding orthodontic brackets in vivo. A combined study using microradiography and confocal laser scanning microscopy. *J Orofac Orthop* 59:265-273, 1998
69. Gorton J, Featherstone JD: In vivo inhibition of demineralization around orthodontic brackets. *Am J Orthod Dentofacial Orthop* 123:10-14, 2003
70. Pascotto RC, Navarro MF, Capelozza Filho L, et al: In vivo effect of a resin-modified glass ionomer cement on enamel demineralization around orthodontic brackets. *Am J Orthod Dentofacial Orthop* 125:36-41, 2004
71. Mellberg JR: Hard-tissue substrates for evaluation of cariogenic and anti-cariogenic activity in situ. *J Dent Res* 71(Spec No):913-919, 1992
72. Benson PE, Pender N, Higham SM: An in situ caries model to study demineralization during fixed orthodontics. *Clin Orthod Res* 2:143-153, 1999
73. Zero DT: In situ caries models. *Adv Dent Res* 9:214-230; discussion 231-234, 1995
74. Doherty UB, Benson PE, Higham SM: Fluoride-releasing elastomeric ligatures assessed with the in situ caries model. *Eur J Orthod* 24:371-378, 2002